



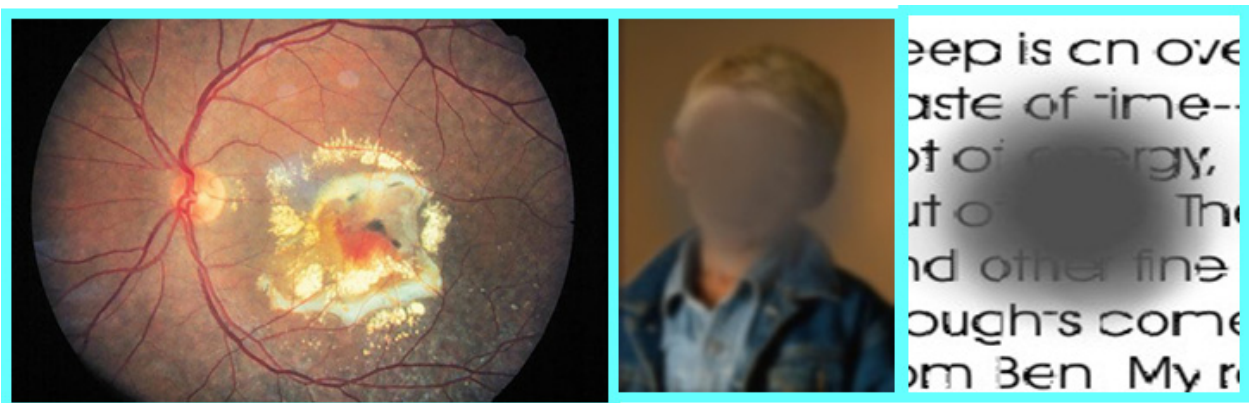
Ajay Kr Bhootra

B.Optom, DOS, FAO, FOAI, FCL~~I~~, ICLEP, FIACLE (Australia)
Diploma in Sportvision (UK)
CEO and DEAN: Krishnalaya School of Optometry

Peeping into future- Age Related Macular Degenerations

One of the tragedies of great old age is to see an agile and absolutely fit person whose eyes have succumbed to ARMD. ARMD is a curse of increasing life expectancy at birth. There are many pre-disposing factor to ARMD, but in some case it may be simply photo-toxicity and lack of proper dietary supplement during early life. Yes, this happens because during the young age we do not resort for any preventive or precautionary care for our eyes. Not many people will believe that using correct tinted lenses or sunglasses during young age might prevent the onset of ARMD during old age.

ARMD is an acquired retinal disorder that is caused by degenerative changes in the retina. The macula in the retina degenerates causing progressive and irreversible loss of central vision. During the initial period, the patient with ARMD may be asymptomatic or may have varying degrees of functional difficulties.



Vision Disturbances

The patient might show following symptoms:

1. Fuzzy and reduced vision
2. Metamorphopsia, i.e, the patient might see distortions and a straight line may appear wavy.
3. Central vision is poor but peripheral vision remains good. Because of reduced central vision reading difficulties increases.
4. Photophobia
5. Color perception is mostly affected as highest concentration of cone cells are within the macula

Visual Field Loss

Central scotomas, i.e, small areas of vision loss at the central visual field is noticed. The objects are seen when they fall on peripheral retina and disappeared when they fall on central scotoma.

Diagnosis of ARMD

The detection of ARMD is not very difficult. The eye care practitioner can detect it during a routine eye examination. During the fundus examination he may notice the presence of drusen – tiny yellow deposits under the retina. The practitioner may map areas of scotoma or distortion on Amsler Grid. Once he detects the presence of ARMD the eye care practitioner may ask you for OCT or Fluorescein angiography or both to establish his diagnosis.

Treatment of ARMD

The disease causes irreversible damage to eye, if detected early it is possible to delay or reduce the severity of the disease. It can be treated with medicines and also by intra-ocular injections. However, the loss of visual acuity and visual field cannot be regained. All treatments are aimed to delay the severity. Most eye surgeons recommend their patients checking their vision with Amsler Grid on regular basis to monitor the progress of the condition.

Low Vision Aids

When spectacle or contact lens stops improving the vision, the patient may be referred for low vision aids services. The following low vision aids might work:

1. Good lighting is very important. Use of extra adjustable lamps for close work is very helpful.
2. Use of strong colors and contrasting colors help.
3. Magnifies with illumination are very effective.
4. Vision rehabilitation is required to promote eccentric viewing.

Acknowledgement:

I am thankful to Dr Sambuddha Kundu, *Medical Vitreo Retinal Fellow and Phaco Surgeon*, who spent his invaluable time to review this article.

References:

- Low Vision Aids Practice, *By Ajay Kr Bhootra*
- Ophthalmic Diagnosis and Treatment *By Myron Yanoff, MD*
- Essentials of Low Vision Practice *By Richard L. Brilliant, OD, FAAO*
